

A Guideline Protocol for the Diagnosis and Assessment of Marfans Syndrome

From the British Society of Echocardiography Education Committee

Richard Steeds, Chair, Julie Sandoval (Lead Author),

Gill Wharton, Nicola Smith, Jane Allen, John Chambers, Richard Jones, Guy Lloyd, Bushra Rana

1. Introduction

1.1 The BSE Education Committee has previously published a minimum dataset for a standard adult transthoracic echocardiogram, available on-line at www.bsecho.org. This document specifically states that the minimum dataset is usually only sufficient when the echocardiographic study is entirely normal. The aim of the Education Committee is to publish a series of appendices to cover specific pathologies to support this minimum dataset.

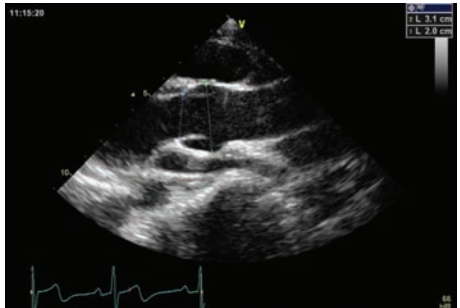
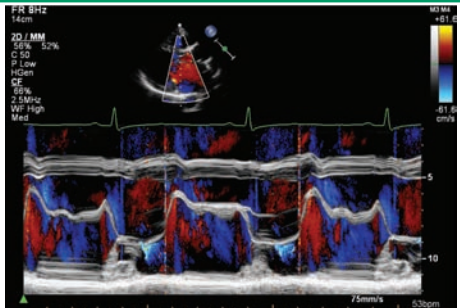
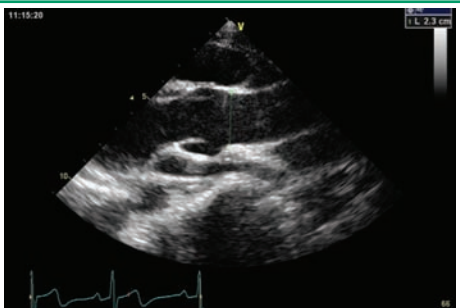
1.2 The intended benefits of such supplementary recommendations are to:

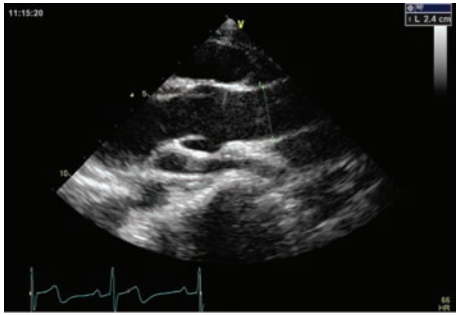
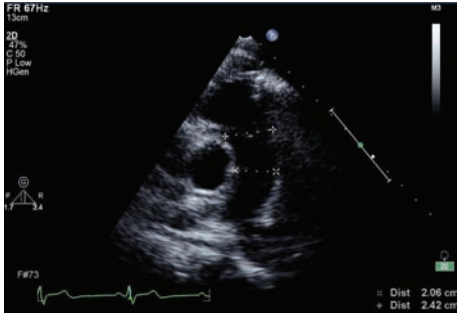
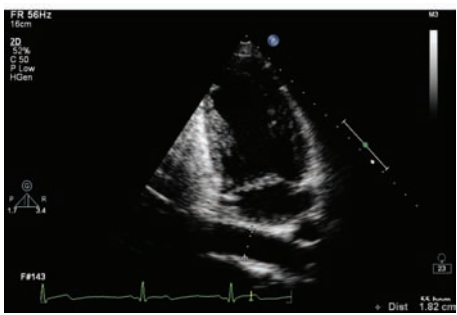
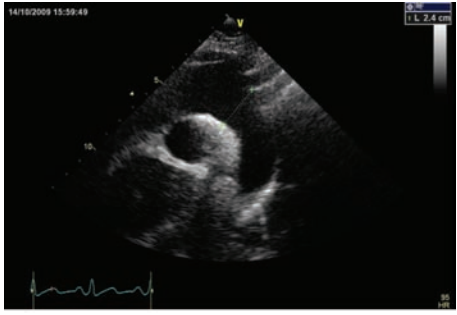
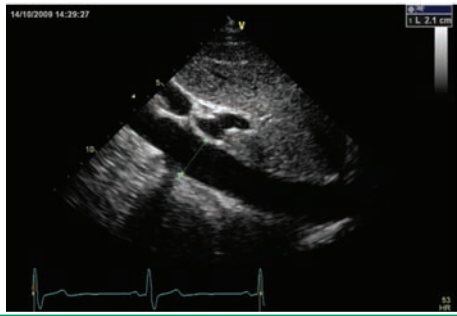
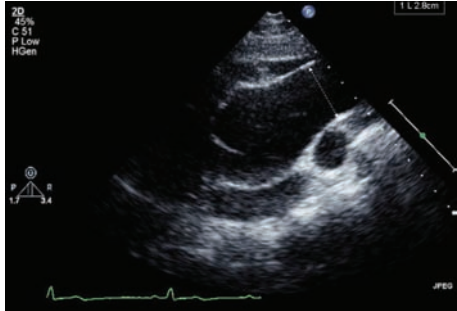
- Support cardiologists and echocardiographers to develop local protocols and quality control programs for adult transthoracic study
- Promote quality by defining a set of descriptive terms and measurements, in conjunction with a systematic approach to performing and reporting a study in specific disease-states
- Facilitate the accurate comparison of serial echocardiograms performed in patients at the same or different sites.

1.3. This document gives recommendations for the image and analysis dataset required in patients either being assessed for or with a known diagnosis of Marfans Syndrome. The views and measurements are supplementary to those outlined in the minimum dataset and assume a full study will be performed in all patients.

1.4 When the condition or acoustic windows of the patient prevent the acquisition of one or more components of the supplementary Dataset, or when measurements result in misleading information (e.g. off-axis measurements), this should be stated.

1.5 This document is a guideline for echocardiography in Marfans Syndrome and will be up-dated in accordance with changes directed by publications or changes in practice.

View	Modality	Measurements	Explanatory Note	Image
PLAX	2D	Aortic annulus Sinus of Valsalva	Hinge point of AV cusps from inner edge to inner edge 2D measurements of the aorta are preferable to m-mode measurements. All aortic diameter measurements should be made from inner edge to inner edge, at the widest diameter*	
PLAX	2D M mode	Mitral valve prolapse	One or both MV leaflets breaks the plane of the MV annulus in a non-symmetric manner and/or may demonstrate myxomatous degeneration Note should be made of MV annulus calcification if seen in any view	
Modifies PLAX	2D	Sino-tubular junction	At junction formed by narrowing of sinuses and tubular ascending aorta	

View	Modality	Measurements	Explanatory Note	Image
Modifies PLAX	2D	Ascending aorta Proximal Mid Distal	Normal dimension less than 2.1cm/m ² **	
PSAX	2D	Pulmonary artery diameter	To check for any dilatation of PA PV annulus (1.7-2.3cm*) PA diameter distal to pulmonary valve (1.5-2.1cm*)	
Modified Apical 2C or Modified PSSAX	2D	Descending thoracic aorta	Normal dimension less than 1.6cm/m ² **	
Transverse Aortic Arch	2D	Aortic arch	Be careful not to include neck vessels in measurement 0.8-1.9cm/m ² ***	
Epigastric region Longitudinal and Transverse imaging	2D	Abdominal aorta (measured at or above the level of the superior mesenteric artery)	Normal dimension less than 1.6cm/m ² **	
Right Parasternal	2D	Ascending aorta and / or root	Further imaging of ascending aorta and aortic root (in some patients this view will provide the best imaging) Normal dimension less than 2.1cm/m ² **	

View	Modality	Measurements	Explanatory Note	Image
Suprasternal or Right Parasternal	2D	Distal ascending aorta	Normal dimension less than 2.1cm/m ² **	

Nomograms for aortic root dimensions are derived from Roman et al Am J Cardiol 1989;64:507-12.

* Lang J Am Soc Echocardiography 2005; 18:1440-1463

** Erbel Heart 2006; 92:137-142; Drexler Am J Cardiol 1990;65:1491-6

*** Rimington and Chambers Echocardiography A Practical Guide for Reporting 2nd edition (2007) p80

Note - The aortic root is defined as the portion of the aorta extending from the basal attachments of the valve cusps within the ventricle to the sino-tubular junction, forming the bridge between the LV and the ascending aorta. (Professor R Anderson)