

A Guideline Protocol for the Assessment of Mitral Stenosis With a View to Balloon Commissurotomy

From the British Society of Echocardiography Education Committee

Hollie Brewerton (Lead Author)

Richard Steeds, Chair

John Chambers

Richard Jones

Prathap Kanagala

Guy Lloyd

Thomas Matthew

David Oxborough

Bushra Rana

Julie Sandoval

Nicola Smith

Gill Wharton

Richard Wheeler

1. Introduction

1.1 The BSE Education Committee has previously published a minimum dataset for a standard adult transthoracic echocardiogram, available on-line at www.bsecho.org. This document specifically states that the minimum dataset is usually only sufficient when the echocardiographic study is entirely normal. The aim of the Education Committee is to publish a series of appendices to cover specific pathologies to support this minimum dataset.

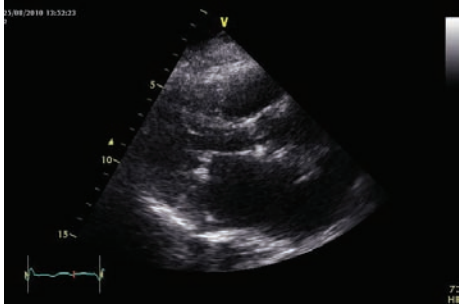
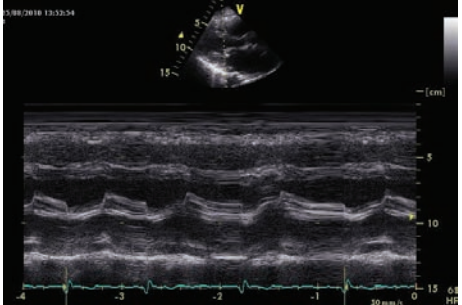
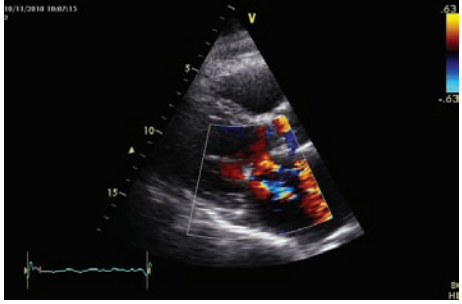
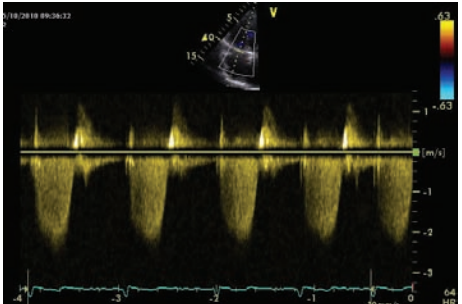
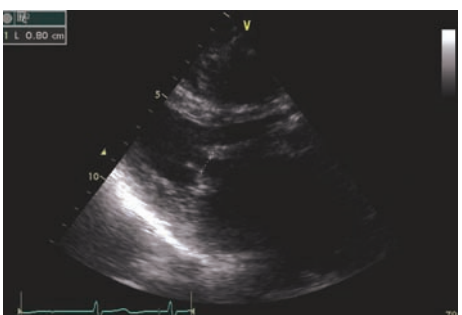
1.2 The intended benefits of such supplementary recommendations are to:

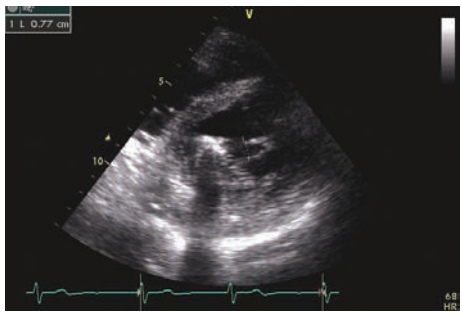
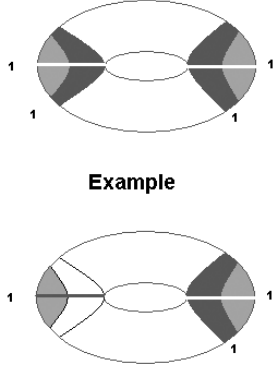
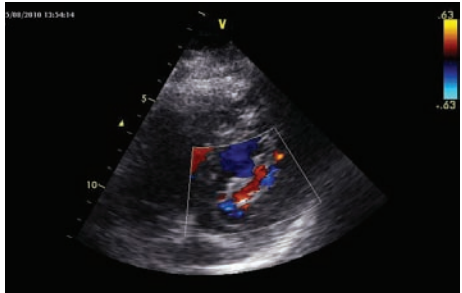
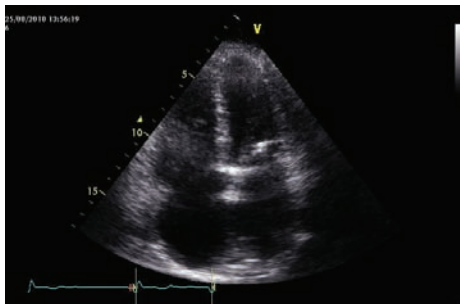
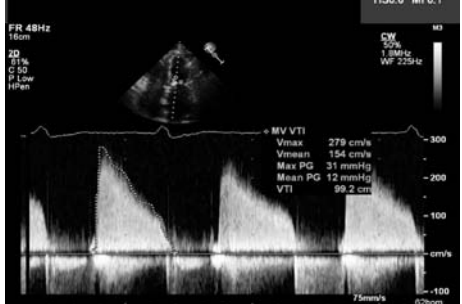
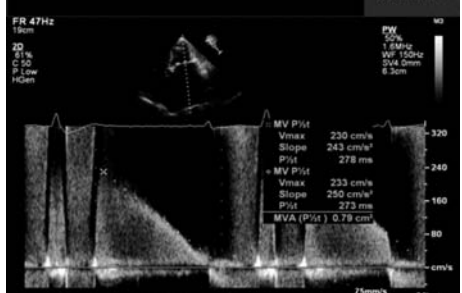
- Support cardiologists and echocardiographers to develop local protocols and quality control programs for adult transthoracic study
- Promote quality by defining a set of descriptive terms and measurements, in conjunction with a systematic approach to performing and reporting a study in specific disease-states
- Facilitate the accurate comparison of serial echocardiograms performed in patients at the same or different sites.

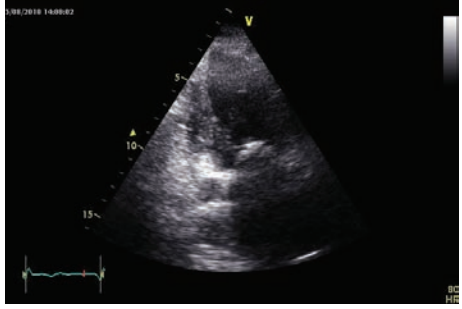
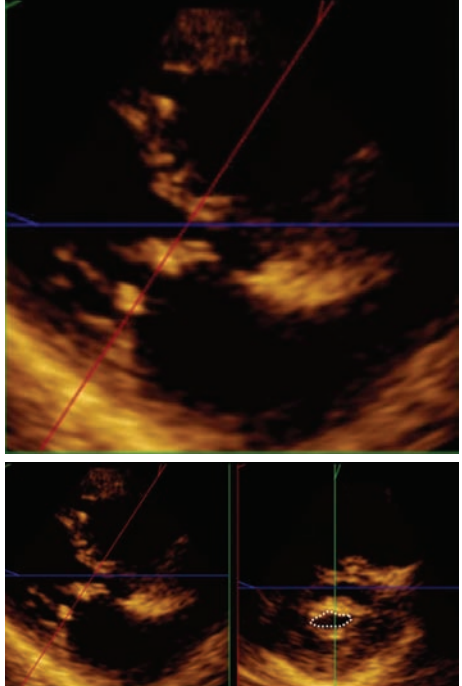
1.3. This document gives recommendations for the image and analysis dataset required in patients being assessed for mitral Stenosis, since echocardiography plays a major role in diagnosis, quantitation of disease severity and analysis of valve anatomy. This protocol gives special emphasis to the identification of valves suitable for percutaneous balloon commissurotomy. The views and measurements are supplementary to those outlined in the minimum dataset and are given assuming a full study will be performed in all patients.

1.4 When the condition or acoustic windows of the patient prevent the acquisition of one or more components of the supplementary Dataset, or when measurements result in misleading information (e.g. off-axis measurements) this should be stated.

1.5 This document is a guideline for echocardiography in the assessment of mitral stenosis with a view to balloon commissurotomy and will be up-dated in accordance with changes directed by publications or changes in practice. It is recognised that not all units will have access to 3D echocardiography but this has been included in expectation of the acquisition of such facilities, since this method of assessment has clear and evidence-based advantages in MV planimetry.

VIEW	Modality	Measurements	Explanatory Note	Image
PLAX	2D	<p>Wilkins Score.¹ Each of the following are scored 0-4 and a combined score above 8 suggests the valve may not be amenable to valvuloplasty</p> <ul style="list-style-type: none"> • Leaflet mobility • Leaflet thickening • Leaflet calcification • Subvalvar involvement 	<p>Leaflet mobility 1 = Mobile, 4 = Immobile</p> <p>Leaflet thickening 1 = Normal less than 5mm, 4 = Severe thickening >8-10mm</p> <p>Leaflet calcification 1 = No bright echoes, 4 = Extensive brightness</p> <p>Subvalvar involvement 1 = Minimal thickening below leaflet tips; 4 = Thickening of all chordal structures</p>	
PLAX	M-mode	MV level	Visual assessment of the degree of excursion and leaflet mobility	
PLAX	Colour Flow Doppler with and without zoom	MV	Quantify severity of MR. More than mild MR is a relative contra-indication to percutaneous balloon mitral commissurotomy (PBMV)	
Modified PLAX	CW Doppler	Pulmonary artery systolic pressure (mmHg)	<p>i) Measure max velocity of TR jet for estimate of RVSP: $PASP = 4V^2 + RA$ (Assess RA from IVC using standard method)</p> <p>ii) Use multiple acoustic windows to optimise angle. Use saline/air/blood contrast if incomplete envelope. $PASP >50\text{mmHg}$ at rest & $>60\text{mmHg}$ following stress is an indication for intervention in moderate MS.</p>	
PSAX MV level	2D	(1) Mitral Valve Area (cm ²) by planimetry	<p>(1)i) Measure maximal excursion at leaflet tips in PLAX</p> <p>ii) Use this dimension to confirm planimetry is to be performed at tips in PSAX. Trace inner edge of MV orifice in mid-diastole, ensuring measurement at the leaflet tips to prevent overestimation of area</p> <p>iii) Set gain to visualize whole of MV orifice. High gain leads to underestimation of MVA</p>	

PSAX PM level	2D	(2) Wilkins Score (3) Commissural calcification score ² Suitability for PBMC may be assessed using Wilkins or Commissural calcification score	(2) Visual assessment of: <ul style="list-style-type: none"> • leaflet thickening • commissural fusion (3) Score graded 0 - 4 (0 = no calcification and 4 = severe calcification of both commissures) is a useful predictor of outcome in PBMC Commissural calcification score of 0, 1 or 2 predict higher valve areas post-PBMC	  <p style="text-align: center;">Example</p> <p style="text-align: center;">Score 1 + 1 + 1 = 3</p>
PSAX MV level	CF Doppler		Origin of any MR in relation to commissures	
Apical 4CH	2D	Wilkins Score	Leaflet mobility 1 = Mobile, 4 = Immobile Leaflet thickening 1 = Normal less than 5mm, 4 = Severe thickening >8-10mm Leaflet calcification 1 = No bright echoes, 4 = Extensive brightness Subvalvar involvement 1 = Minimal thickening below leaflet tips; 4 = Thickening of all chordal structures	
Apical 4CH	CW Doppler	Mean Gradient (mmHg)	i) Use CF to identify highest flow velocity zone in eccentric jets ii) Trace CW profile to obtain mean gradient $P = 4V^2$ iii) Subject to variation with heart rate, cardiac output, MR (Set sweep speed to obtain optimal profile e.g. 100m/sec)	
Apical 4CH	CW Doppler	Pressure Half-Time (ms) and Mitral Valve Area by P1/2 (cm ²)	i) Measure deceleration slope in mid-diastole at increased sweep speed (average 3 cycles) ii) $MVA = 220/P_{1/2}$ for MV area (cm ²) Optimal accuracy for MVA 1-1.5cm ² iii) Invalid post-PBMC and in conditions of altered LV compliance	

Apical 2CH & Apical 3CH	2D	Wilkins Score	<p>Leaflet mobility 1 = Mobile, 4 = Immobile</p> <p>Leaflet thickening 1 = Normal less than 5mm, 4 = Severe thickening >8-10mm</p> <p>Leaflet calcification 1 = No bright echoes, 4 = Extensive brightness</p> <p>Subvalvar involvement 1 = Minimal thickening below leaflet tips; 4 = Thickening of all chordal structures</p>	
PLAX (preferred) Or Apical 4CH	3D	Mitral Valve Area (cm ²) by planimetry. Use two orthogonal planes (red and green) to ensure the planimetry is performed at the MV tips	<p>Preferred PLAX</p> <ul style="list-style-type: none"> • Full volume acquisition • Live zoom acquisition <p>Or Apical 4CH</p> <ul style="list-style-type: none"> • Full volume acquisition • Live zoom acquisition 	
Other Considerations		<p>BP/HR & rhythm should always be reported</p> <p>Quantify MS Severity (mild/moderate/severe). Specify method used to calculate MVA in report</p> <p>LA size</p> <p>RV dimensions</p> <p>RV function</p> <p>Other valves for rheumatic process</p> <p>TOE</p> <p>Exercise stress</p>	<p>See BSE Valve Guidelines. If discrepancy between mean gradient, P1/2 and planimetry, consider MVA by continuity equation and MVA by PISA methods.</p> <p>See BSE Chamber Quantification</p> <p>See BSE Chamber Quantification</p> <p>TAPSE, TDI</p> <p>Exclude significant aortic stenosis: AS may be under-estimated due to low flow in severe MS</p> <p>Consider if inadequate TTE views and perform before PBMC to exclude LAA thrombus</p> <p>Consider if discrepancy between patient symptoms and grade of severity to re-assess mean gradient and PA systolic pressure.</p>	

References

1. Wilkins Br Heart J 1988;60:299
2. N. Sutaria Heart 2000 October;84(4):398-402