

NEW GUIDELINES

A Guideline Protocol for the Assessment of Patients with Suspected Pulmonary Hypertension.

From the British Society of Echocardiography Education Committee

David Dawson, Julia Grapsa, Petros Nihoyannopoulos (Lead Authors)

Richard Steeds (Chair), Nicola Smith, Julie Sandoval, Gill Wharton, Jane Allen, Prathap Kanagala, John Chambers, Richard Jones, Matthew Thomas, Richard Wheeler, Guy Lloyd

1. Introduction

1.1 The BSE Education Committee has previously published a minimum dataset for a standard adult transthoracic echocardiogram, available on-line at www.bsecho.org. This document specifically states that the minimum dataset is usually only sufficient when the echocardiographic study is entirely normal. The aim of the Education Committee is to publish a series of appendices to cover specific pathologies to support this minimum dataset.

1.2 The intended benefits of such supplementary recommendations are to:

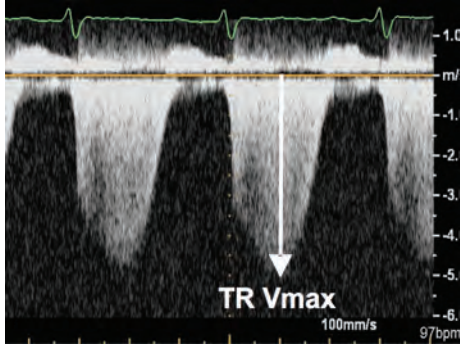
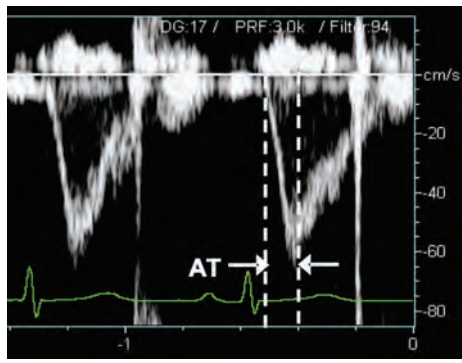
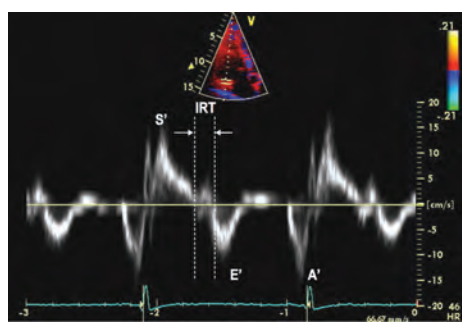
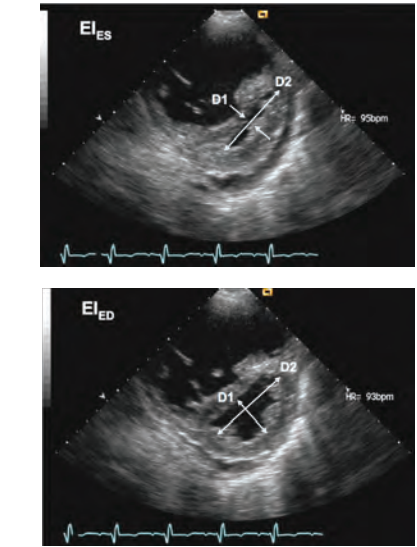
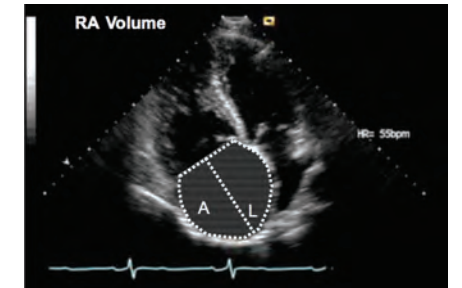
- Support cardiologists and echocardiographers to develop local protocols and quality control programs for adult transthoracic study
- Promote quality by defining a set of descriptive terms and measurements, in conjunction with a systematic approach to performing and reporting a study in specific disease-states
- Facilitate the accurate comparison of serial echocardiograms performed in patients at the same or different sites.

1.3. This document gives recommendations for the image and analysis dataset required in patients being assessed for suspected pulmonary hypertension. The views and measurements are supplementary to those outlined in the minimum dataset and are given assuming a full study will be performed in all patients.

1.4 When the condition or acoustic windows of the patient prevent the acquisition of one or more components of the supplementary Dataset, or when measurements result in misleading information (e.g. off-axis measurements) this should be stated.

1.5 This document is a guideline for echocardiography in the assessment of patients with suspected pulmonary hypertension and will be up-dated in accordance with changes directed by publications or changes in practice.

VIEW	Modality	Measurements	Explanatory Note	Image
PLAX	2D	<p>RV:LV Diastolic Ratio</p> <ul style="list-style-type: none"> Qualitative Identify pericardial effusion as a marker of adverse prognosis 	<p>RV:LV ratio cutoff >0.5:1</p> <ul style="list-style-type: none"> Significance: Diagnostic An assessment of RV enlargement 	
A4CH	2D	<p>RV Minor/Major Axis Dimensions (RVd)</p> <ul style="list-style-type: none"> Quantitative <p>RV Diastolic and Systolic Area (RVAd/s)</p> <ul style="list-style-type: none"> Quantitative—calculate Fractional Area Change¹ 	<ul style="list-style-type: none"> See BSE Guidelines: Chamber Quantification Significance: Diagnostic An assessment of RV size and function 	
A4CH	M-mode	<p>Tricuspid Systolic Annular Plane Excursion (TAPSE)</p> <ul style="list-style-type: none"> M-mode cursor across lateral tricuspid annulus Select a fast sweep speed. Measure total excursion of the tricuspid annulus 	<p>TAPSE cutoff <1.6 cm</p> <ul style="list-style-type: none"> See BSE Guidelines: Chamber Quantification Significance: Diagnostic A measure of longitudinal RV systolic function² 	
PSAX	2D M-mode	<p>Inferior Vena Cava Diameter (IVC)</p> <ul style="list-style-type: none"> At end diastole and end-expiration. Perpendicular to the IVC long axis. Approx 1.0 – 2.0 cm from the RA junction. Assess % reduction in diameter with sniffing. 	<p>See BSE Guidelines: Chamber Quantification</p> <ul style="list-style-type: none"> Significance: Diagnostic & Prognostic Indicator of RV filling pressure Consider assessing hepatic vein flow to supplement accuracy³ 	

<p>A4C PSAX</p>	<p>CW</p>	<p>Peak tricuspid regurgitant velocity (TR V_{max})</p>	<p>TR V_{max} cutoff >2.6 m/s >2.8 m/s if obese >2.9 m/s if >60 yrs</p> <ul style="list-style-type: none"> • Significance: Diagnostic⁴ • A indicator of pulmonary pressure in the absence of pulmonary stenosis • Consider agitated saline/air/blood contrast if incomplete envelope⁵ 	
<p>PSAX</p>	<p>PW</p>	<p>RV outflow tract acceleration time (AT)</p> <p>Held end-expiration Onset of flow to peak velocity</p>	<p>RVOT AT cutoff <105 ms</p> <ul style="list-style-type: none"> • Significance: Diagnostic⁶ • Surrogate measure of PA pressure 	
<p>A4CH</p>	<p>PW TDI</p>	<p>Isovolumetric relaxation time (IVRT)</p> <ul style="list-style-type: none"> • Sample volume at basal lateral RV myocardium • Held end-expira-tion • Offset of S' wave to onset E' wave 	<p>RV IVRT cutoff >75 ms</p> <ul style="list-style-type: none"> • Significance: Diagnostic. A value below 40ms has a high negative predictive value for PHT⁷ • A measure of RV dysfunction. 	
<p>PSAX</p>	<p>2D</p>	<p>Eccentricity Index (EI)</p> <p>EI = D2/D1</p> <p>Where: D1 = Minor axis dimension perpendicular to septum</p> <p>D2 = Minor axis dimension perpendicular to D1</p>	<p>EI cutoff >1.0</p> <ul style="list-style-type: none"> • Significance: Prognostic⁸ • EI end systole an expression pressure overload • EI end diastole an expression volume overload 	
<p>A4CH</p>	<p>2D</p>	<p>RA Volume (RAV)</p> <p>Where: RAV=0.85(A2)/L</p>	<p>RAVI male cutoff >33 m/m2</p> <p>RAVI female cutoff >27 ml/m2</p> <ul style="list-style-type: none"> • Significance: Prognostic⁹ 	

A4CH	PW TDI	RV S' Wave Velocity <ul style="list-style-type: none"> • Sample volume at basal lateral RV myocardium 	S' wave velocity cutoff : <12 cm/s <ul style="list-style-type: none"> • Significance: Diagnostic ¹⁰ • Expression of RV longitudinal systolic function 	
A4CH	PW TDI	RV MPI <p>MPI= a-b/b</p> <p>Where: a = A' offset to E' onset b = S' onset to S' offset</p>	<ul style="list-style-type: none"> • RV MPI cut off: >0.32 • Significance: Prognostic ¹¹ • Expression of RV systolic and diastolic performance 	

References

1. Ghio S, et al. Prognostic relevance of the echocardiographic assessment of right ventricular function in patients with idiopathic pulmonary arterial hypertension. *Int J Cardiol* 2008;140:272-280.
2. Forfia PR et al. Tricuspid annular displacement predicts survival in pulmonary hypertension. *Am J Respir Crit Care Med* 2006;174:1034-1041.
3. Brennan JM, et al. Reappraisal of the Use of Inferior Vena Cava for Estimating Right Atrial Pressure. *J Am Soc Echocardiogr* 2007;20:857-861.
4. McQuillan BM, et al. Clinical correlates and reference intervals for pulmonary artery systolic pressure among echocardiographically normal subjects. *Circ* 2001;104:2797-2802.
5. Jeon DS, et al. The Usefulness of a 10% Air-10% Blood-80% Saline Mixture for Contrast Echocardiography: Doppler Measurement of Pulmonary Artery Systolic Pressure. *J Am Coll Cardiol* 2002;39:124-129.
6. Kitabatake A, et al. Noninvasive evaluation of pulmonary hypertension by a pulsed doppler technique. *Circ* 1983;68:302-309.
7. Brechat N, et al. Usefulness of right ventricular isovolumic relaxation time in predicting systolic pulmonary artery pressure. *Eur J Echocardiogr* 2008;9:547-554.
8. Ryan T, et al. An echocardiographic index for separation of right ventricular volume and pressure overload. *J Am Coll Cardiol* 1985;5:918-927.
9. Raymond RJ, et al. Echocardiographic predictors of adverse outcomes in primary pulmonary hypertension. *J Am Coll Cardiol* 2002;39:1214-1219.
10. Melek M, et al. Tissue Doppler evaluation of tricuspid annulus for estimation of pulmonary artery pressure in patients with COPD. *Lung* 2006;184:121-31.
11. Yeo TC, et al. Value of a Doppler-derived index combining systolic and diastolic time intervals in predicting outcome in primary pulmonary hypertension. *Am J Cardiol* 1998;81:1157-1161.